FONDAZIONE CENTRO CARDIOLOGIA
E CARDIOCHIRURGIA A. DE GASPERIS
Niguarda Ca' Granda

Azienda Ospedaliera
Ospedale Niguarda Ca'Granda

Dipartimento Cardiologico A. De Gasperis
Azienda Ospedaliera Niguarda Ca' Granda - Milano

HOW TO - IL PAZIENTE DA RESINCRONIZZARE
RM CARDIACA

Giuseppina Quattrocchi
Laboratorio di RM cardiaca – Cardiologia IV- Ospedale Niguarda Ca' Granda- Milano

Perche' la RM?

-Morfologia e funzione

Studio cinesi e funzione

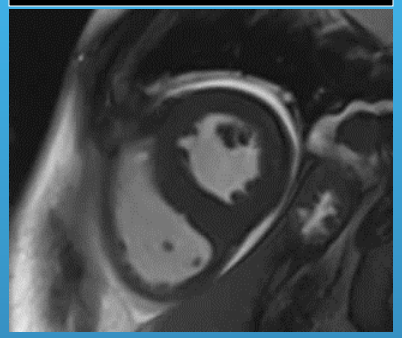

Strain

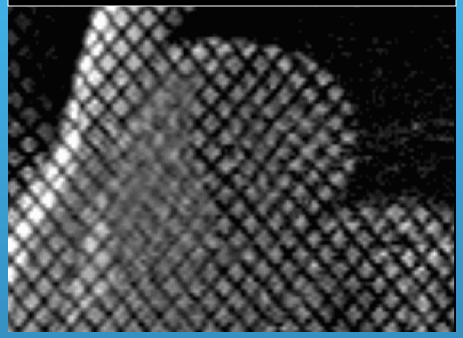

Perfusione

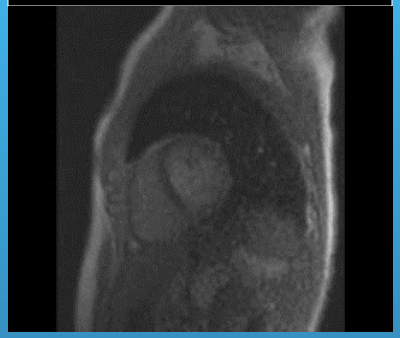

Flussi e gradienti



-Caratterizzazione tissutale

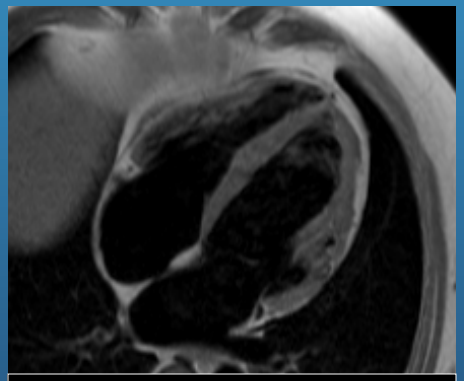

Immagini T1 pesate=
Infiltrazione adiposa

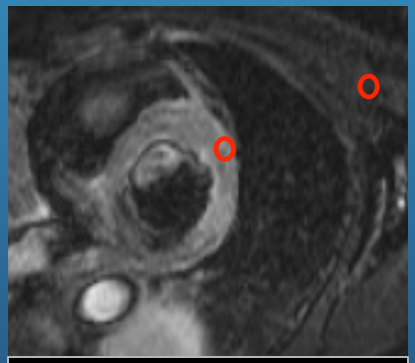

Immagini T2 pesate STIR
Edema/flogosi

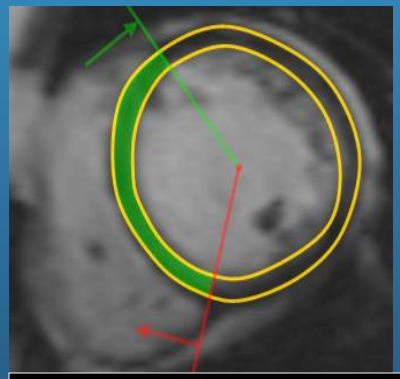

Sequenze T2*
Ferro cardiaco

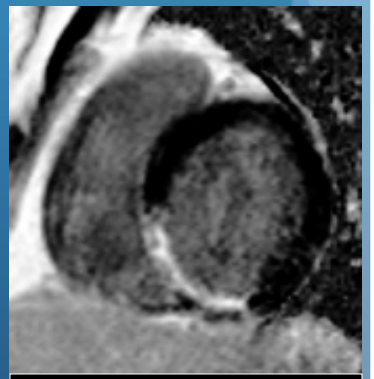

Delayed enhancement
Fibrosi e cicatrici

RM NELLA RESINCRONIZZAZIONE CARDIACA

STUDIO DELLA FUNZIONE SISTOLICA

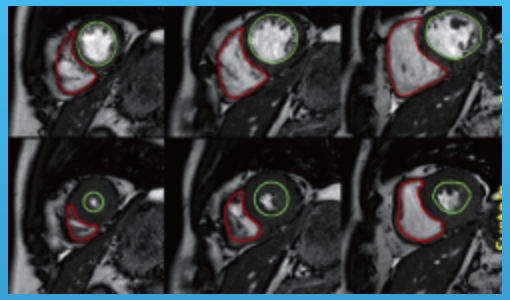

STUDIO DELLA DISSINCRONIA VENTRICOLARE

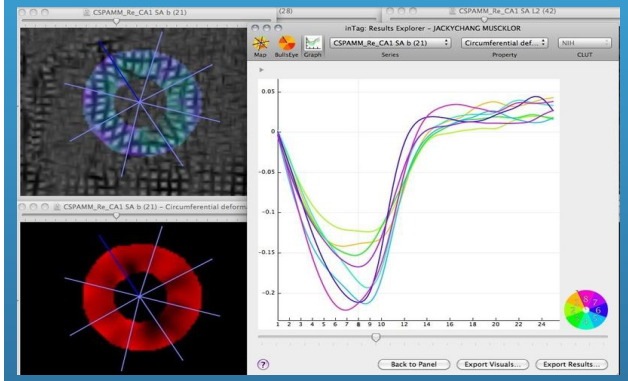

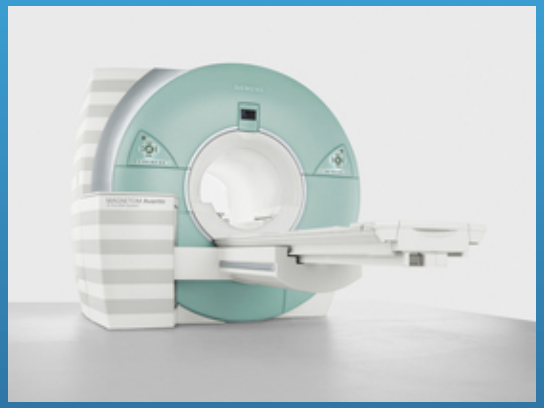

VALUTAZIONE DI FIBROSI E CICATRICI MIOCARDICHE

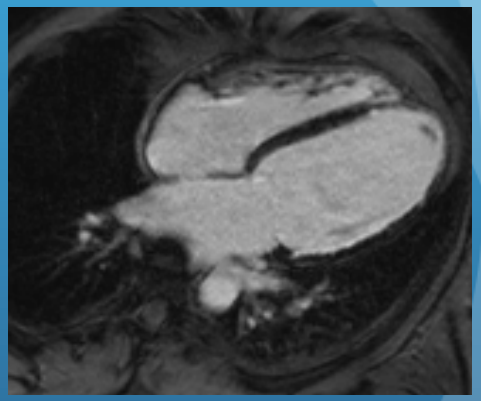

VALUTAZIONE DEL SISTEMA VENOSO CORONARICO

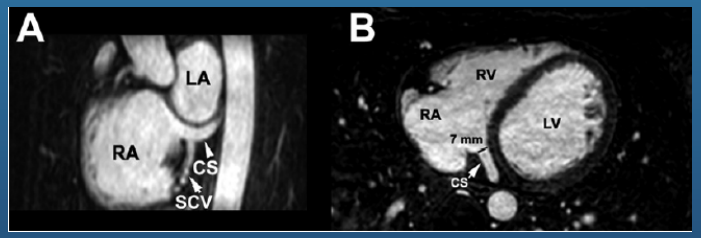

STUDIO DELLA FUNZIONE SISTOLICA

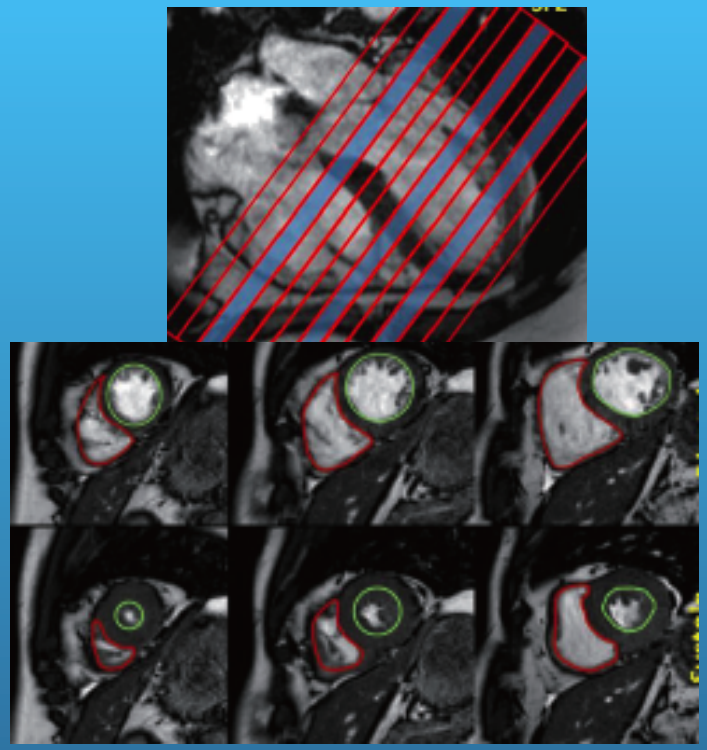



La RMC e' il gold standard per il calcolo dei volumi, della funzione sistolica biventricolare e della massa

Lancet 1985, Radiology 1990, 2005; J CMR 2003; Circulation 2008

STUDIO DELLA FUNZIONE SISTOLICA

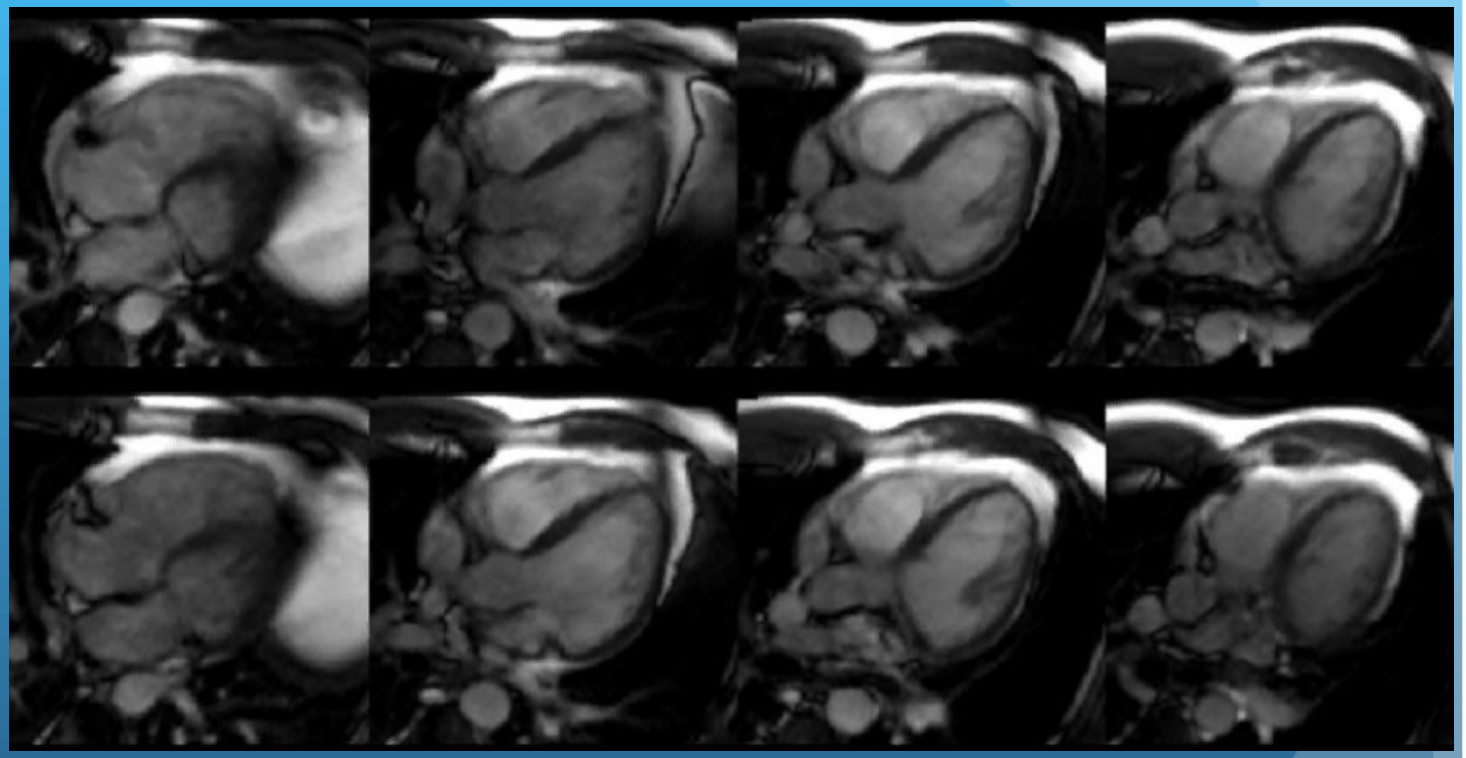

VALUTAZIONE MORFOLOGIA E FUNZIONE DEL VDX

RM NELLA RESINCRONIZZAZIONE CARDIACA

Alpendurada *et al. Journal of Cardiovascular Magnetic Resonance* 2011, **13**:68
http://www.jcmr-online.com/content/13/1/68

Journal of Cardiovascular Magnetic Resonance

RESEARCH **Open Access**

Right ventricular dysfunction is a predictor of non-response and clinical outcome following cardiac resynchronization therapy

Francisco Alpendurada[1], Kaushik Guha[2], Rakesh Sharma[2], Tevfik F Ismail[1], Amy Clifford[1], Winston Banya[3], Raad H Mohiaddin[1], Dudley J Pennell[1], Martin R Cowie[2], Theresa McDonagh[4] and Sanjay K Prasad[1*]

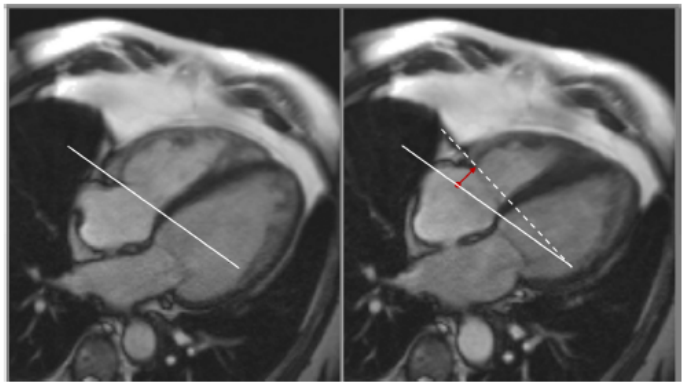

Figure 2 Four-chamber view in end-diastole (left panel) and end-systole (right panel). The tricuspid annular plane is marked as a white line in diastole and as a dashed line in systole. The red vector represents the tricuspid annular systolic excursion (TAPSE).

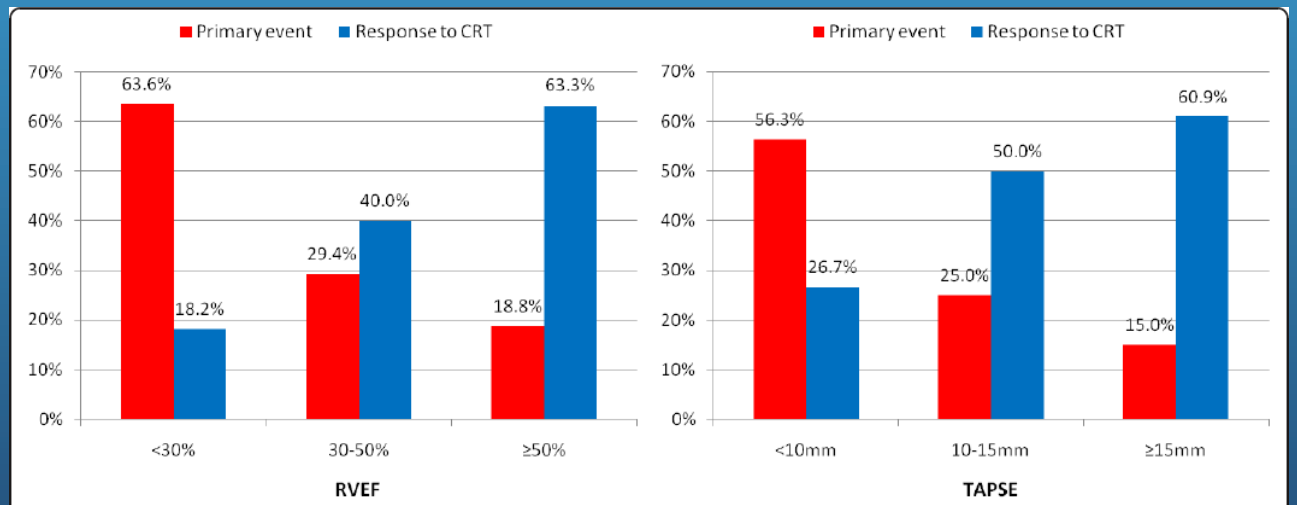

Figure 4 Frequency of primary events and response to CRT for different ranges of RVEF and TAPSE.

60 HF pz
End Point primario:morte per tutte le cause
ed ospedalizzazione
End Point secondario: risposta alla terapia

STUDIO DELLA DISSINCRONIA VENTRICOLARE

CINE SSFP IMAGING

PHASE CONTRAST IMAGING

MYOCARDIAL TAGGING

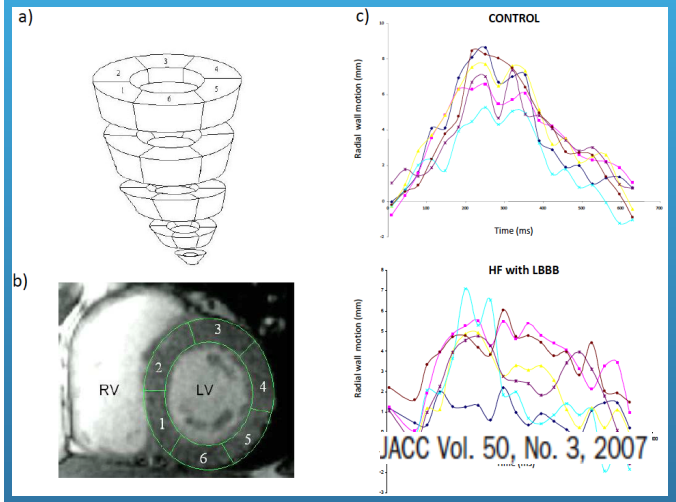

Radial myocardial velocity

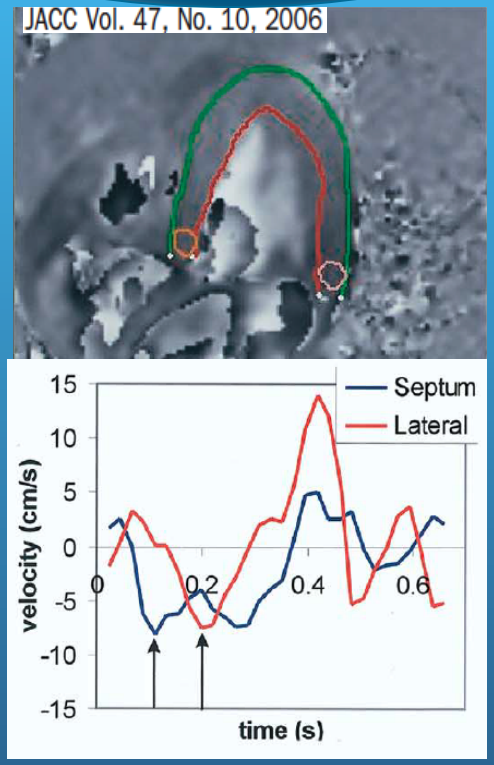

Longitudinal myocardial velocity

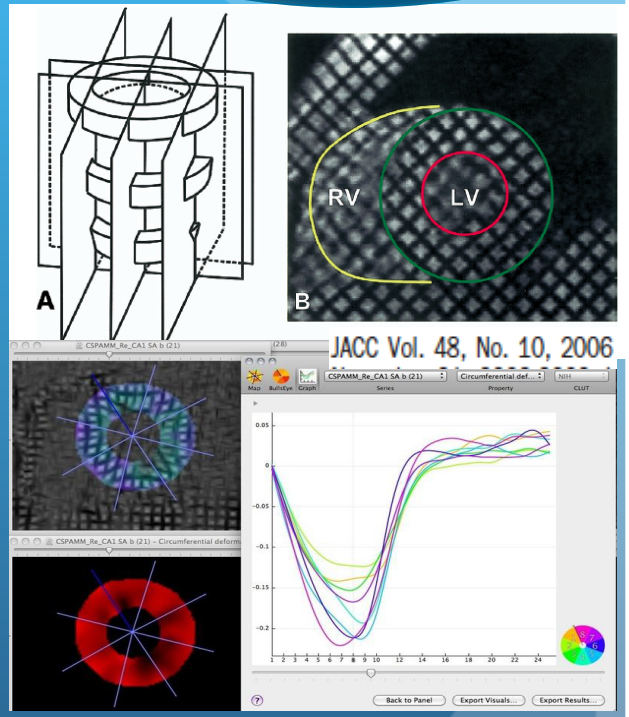

Circumferential myocardial velocity

STUDIO DELLA DISSINCRONIA VENTRICOLARE

Table 2. Dyssynchrony Evaluation by CMR

Technique	Characteristics	Advantages	Disadvantages	Dyssynchrony Indices	Prediction of CRT Response
Cine					
SSFP	Wall motion	Myocardial borders well seen	Automated or semi-automated contour detection often requires manual correction Time consuming	Septal-lateral delay of wall thickening (>65 ms) Radial dyssynchrony (tissue synchronization index)	SN, 90%; SP, 59% (n=40) (septal-lateral delay) Could not further stratify patients (radial dyssynchrony) (n=225)
Phase contrast					
MR-TVM	Tissue velocity mapping	3D velocity information per pixel Velocities used to derive strain Measures interventricular dyssynchrony	Similar to above Long scan time to acquire images Respiratory artifact	Aorta-pulmonary onset flow time difference for interventricular dyssynchrony (RV-LV) (milliseconds)	No studies
DENSE	Enco position displace				No studies
Tagged imaging					
SPAMM	SPAM				PPV, 87% NPV, 100% to improve patient selection (circumferential uniformity ratio estimate) (n=47)
CSPAMM	Subtraction of phase tag to give improved persistence of tag lines			ratio estimate)	
HARP	Analysis of tagged images in the frequency domain	Automated "Faster" 2D and 3D HARP	Up to 45 min processing time		
SENC	Sinusoidal tags applied in the slice plane	Fastest postprocessing Instantaneous real-time quantitative strain Higher spatial resolution Through-plane encoding allows circumferential and longitudinal strain	Not widely available Analysis is complex		

CMR indicates cardiac MRI; CRT, cardiac resynchronization therapy; CSPAMM, complementary spatial modulation of magnetization; DENSE, displacement encoding with stimulated echoes; HARP, harmonic phase analysis; LV, left ventricle; MR-TVM, magnetic resonance tissue velocity mapping; N/A, not applicable; NPV, negative predictive value; PPV, positive predictive value; RV, right ventricle; SENC, strain-encoded MRI; SN, sensitivity; SP, specificity; SPAMM, spatial modulation of magnetization; SSFP, steady-state free precession.

LIMITI
-Metodi di valutazione poco diffusi
-Necessita' di software costosi
-Postprocessing elaborato
-Necessita' di specifica expertise

AlJaroudi et al Nonechocardiographic Imaging of CRT
Circ Cardiovasc Imaging May 2011

VALUTAZIONE DI FIBROSI E CICATRICI MIOCARDICHE

CARATTERIZZAZIONE TISSUTALE POSTCONTRASTO

- La fibrosi miocardica rappresenta storicamente una variabile diagnostica e prognostica di grande rilevanza, acquisita post mortem o con biopsia endomiocardica.La RM cardiaca e' l'unica metodica diagnostica per valutare in vivo sede ed estensione della fibrosi in modo accurato, riproducibile e non invasivo.

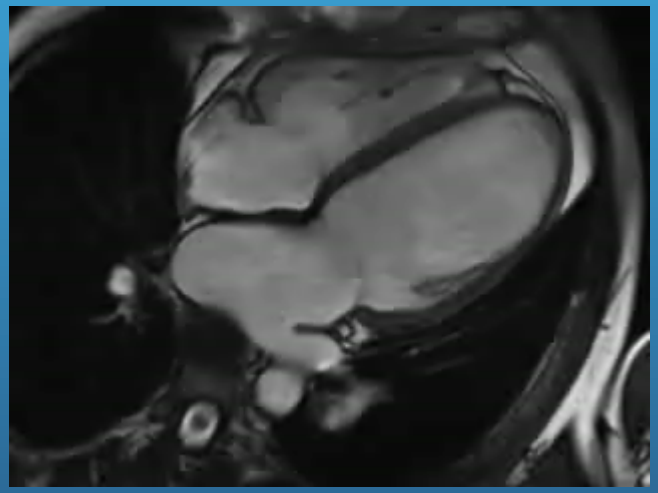

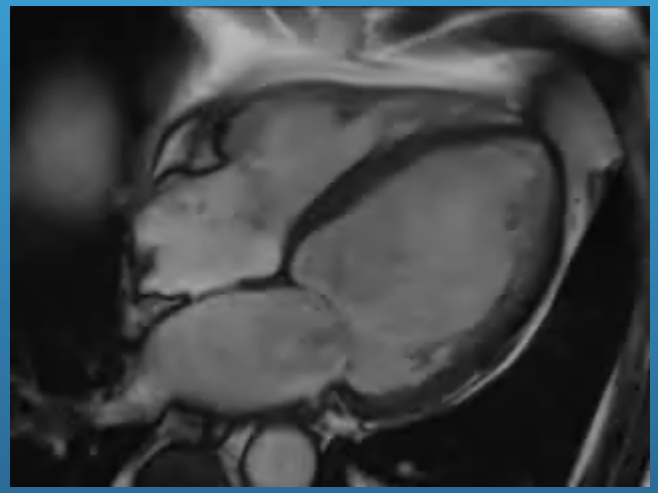

Gadolinio: mezzo di contrasto extravascolare ed extracellulare

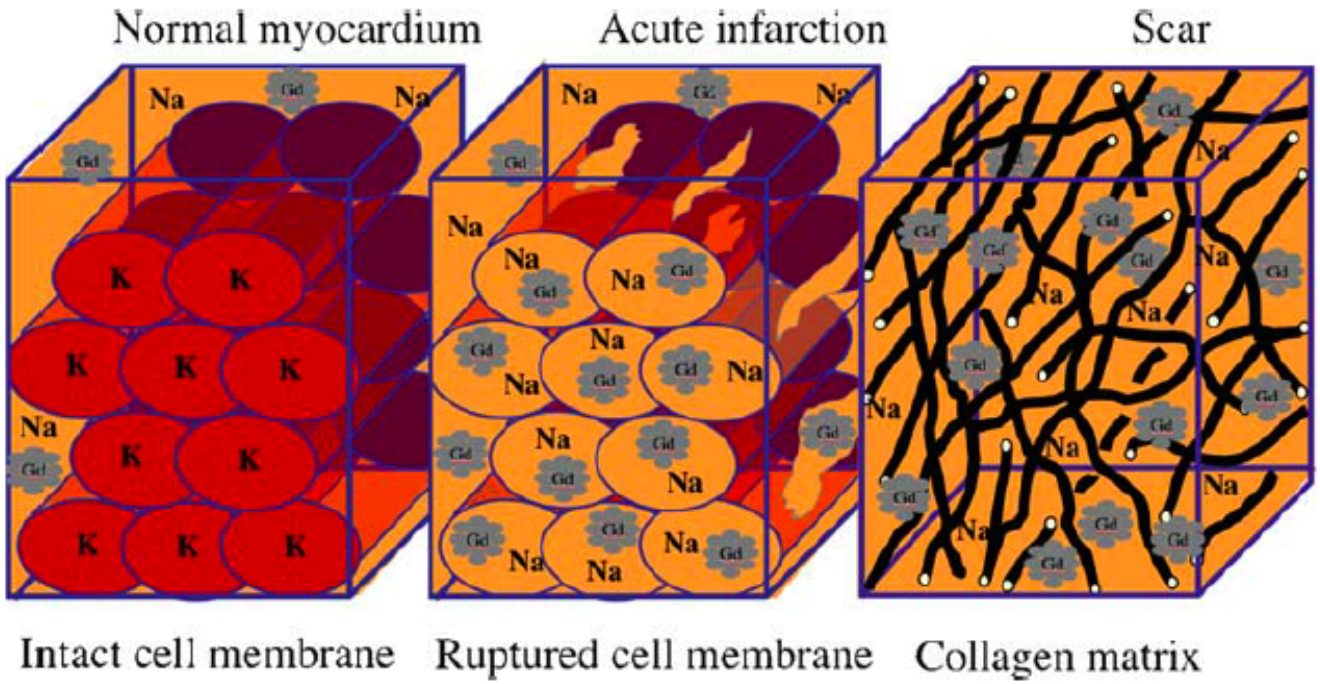

FIGURE 1.5. The volume of distribution for gadolinium is increased in both acute and chronic infarcts. (From Shah et al, Myocardial Viability. In: Edelman et al, eds. *Clinical Magnetic Resonance Imaging (3rd ed.)*. New York, NY: Elsevier; 2006)

VALUTAZIONE DI FIBROSI E CICATRICI MIOCARDICHE

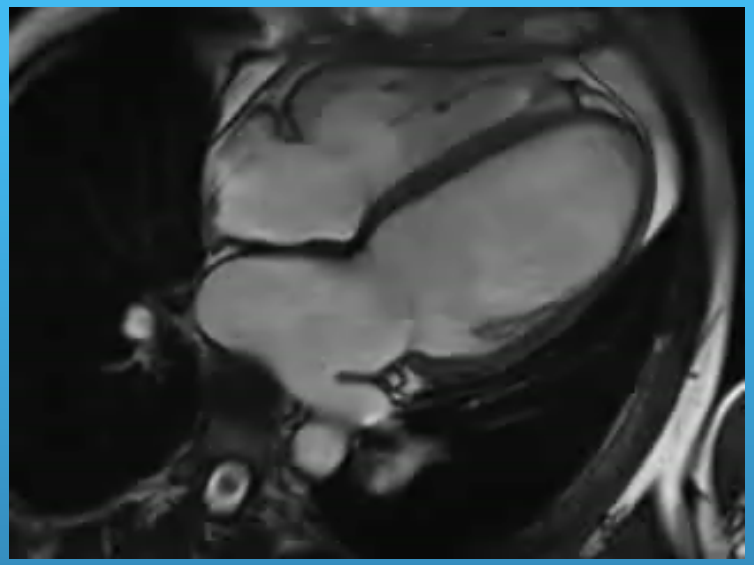

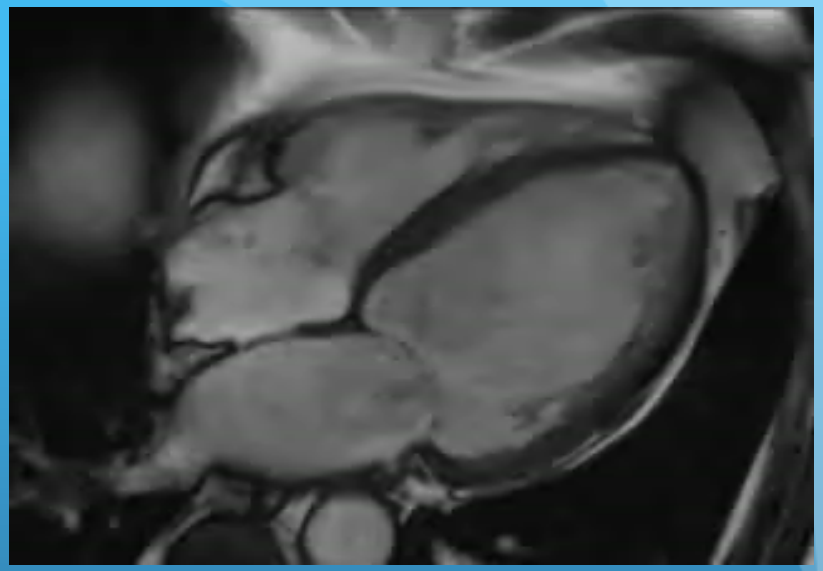

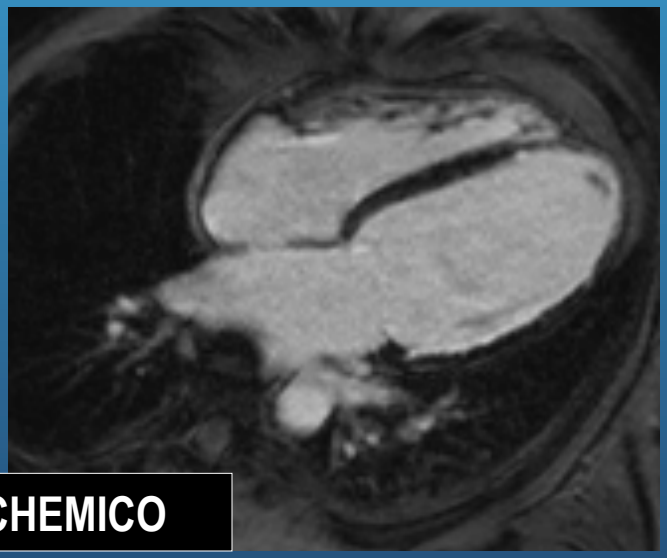

LE ISCHEMICO

LE NON ISCHEMICO

VALUTAZIONE DI FIBROSI E CICATRICI MIOCARDICHE

DIFFERENTI PATTERN DI LGE RILEVABILI NELLA PRATICA CLINICA

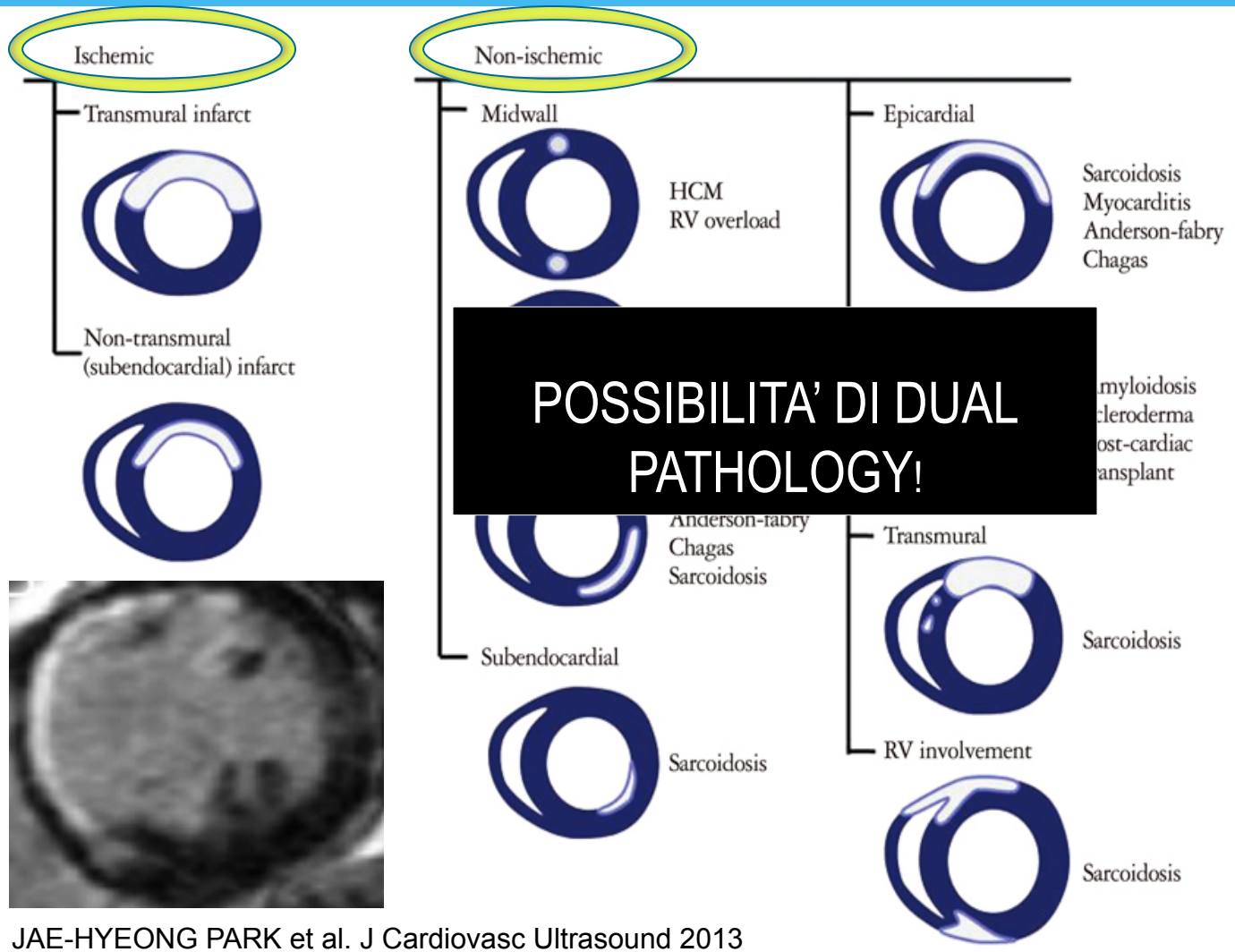

POSSIBILITA' DI DUAL PATHOLOGY!

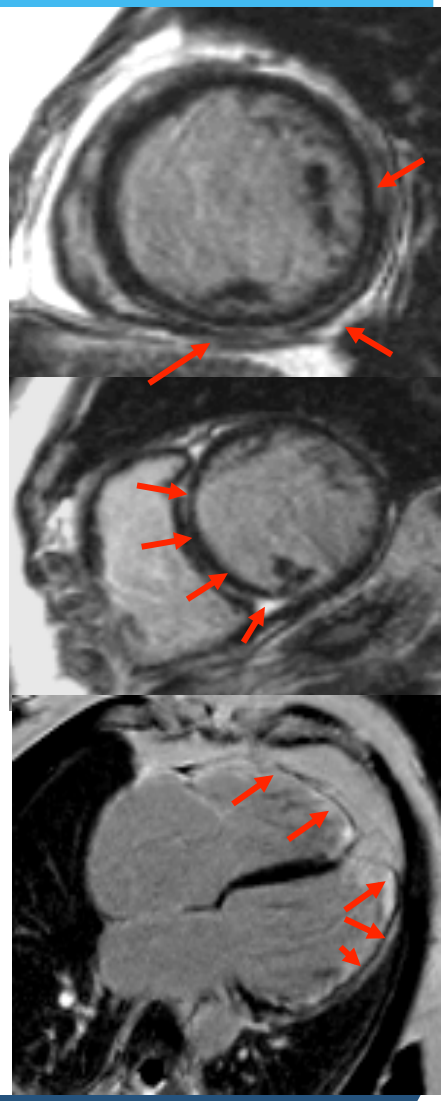

JAE-HYEONG PARK et al. J Cardiovasc Ultrasound 2013

VALUTAZIONE DI FIBROSI E CICATRICI MIOCARDICHE

ANALISI QUANTITATIVE E METODI DI CALCOLO

Manual Tracing

1.38 ml

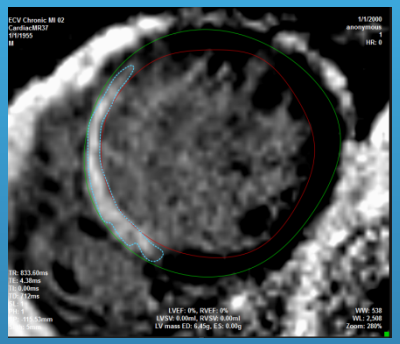

Manual Threshold

1.72 ml

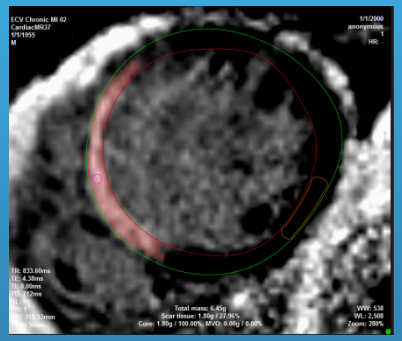

Time consuming
Operator dependent

FWHM

1.73 ml

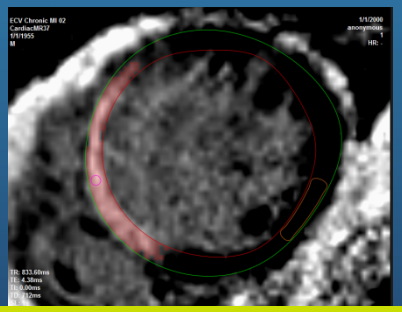

SD 4

1.83 ml

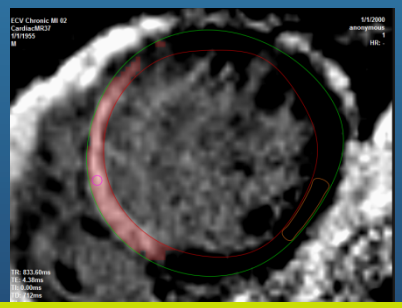

SD 6

1.27 ml

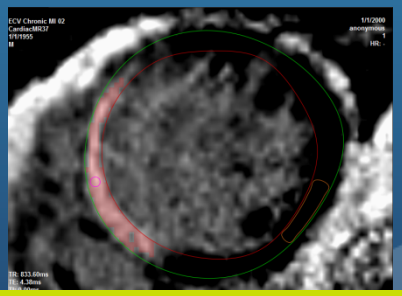

Rapid
Accuracy??

VALUTAZIONE DI FIBROSI E CICATRICI MIOCARDICHE

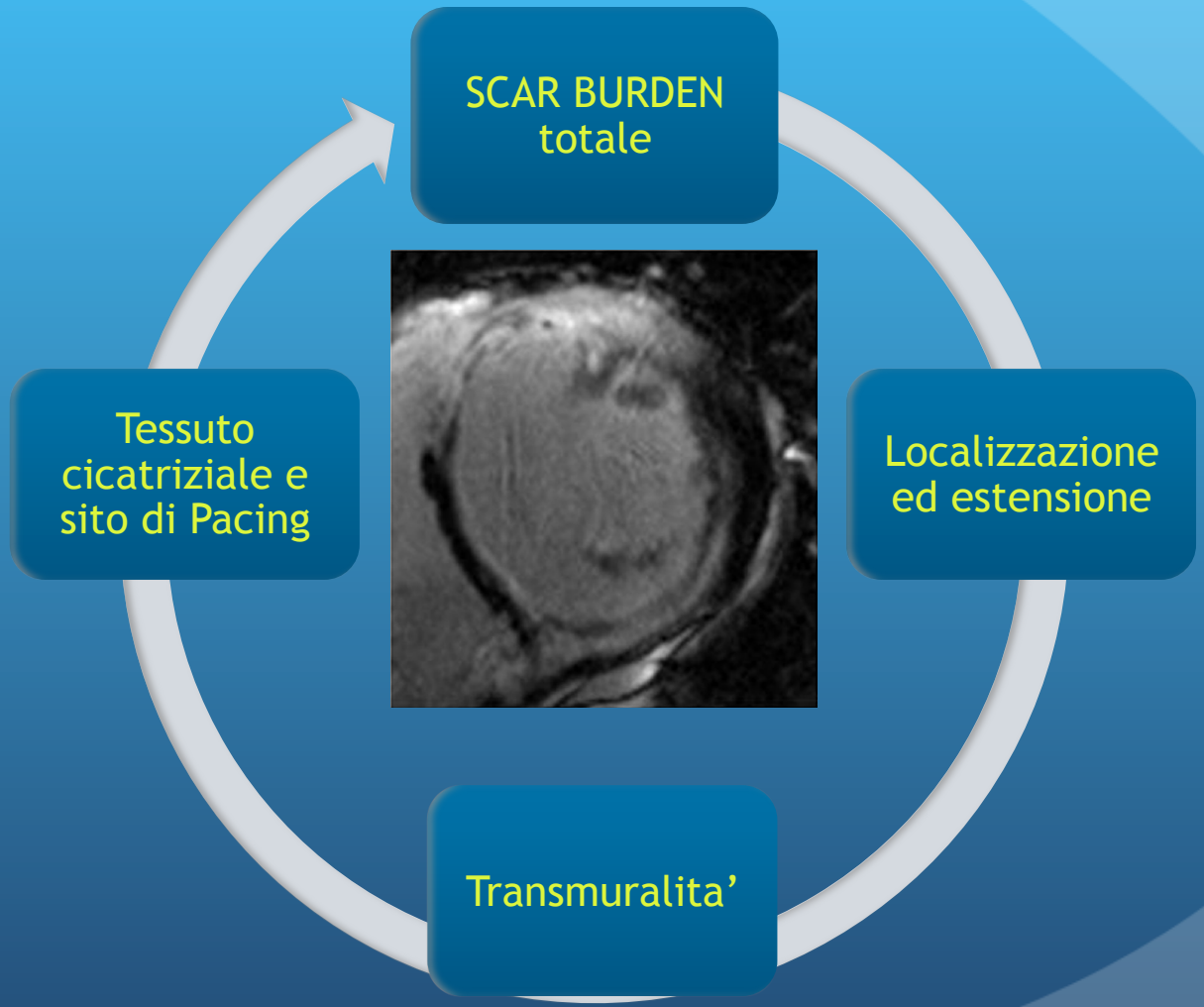

VALUTAZIONE DI FIBROSI E CICATRICI MIOCARDICHE

LE posterolaterale transmurale nel 35% dei pts

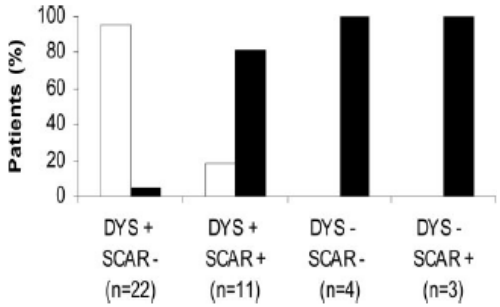

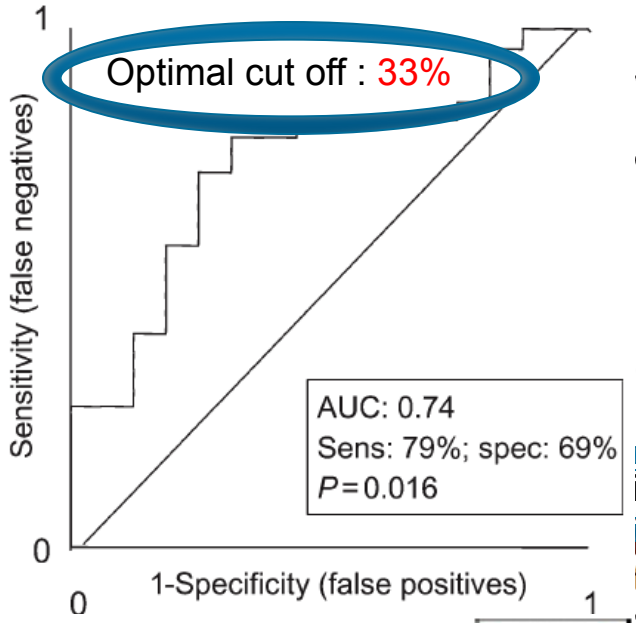

Chalil et al_Europace 2007; 9: 1031-37

N= 45 CRT patients
Only ischemic etiology

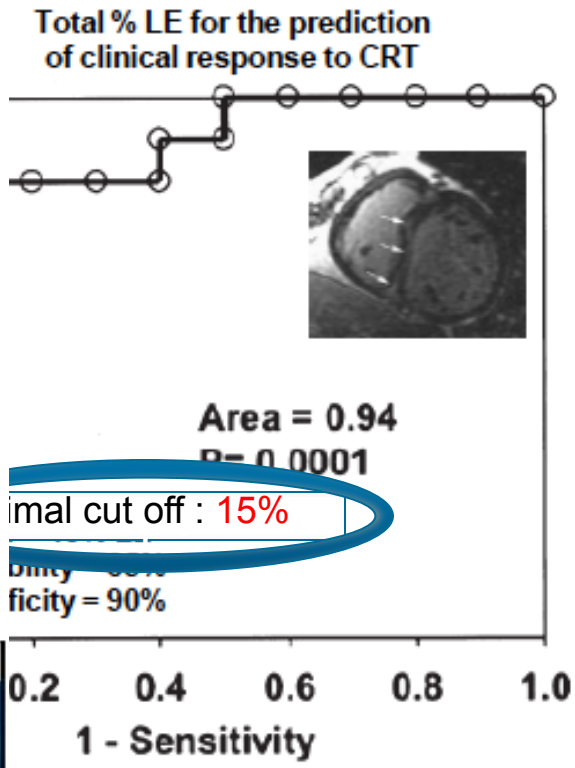

BLEEKER et al, CIRCULATION 2006
40 HF pz
Eziologia ischemica
FU 6 mesi
Risposta (70% pz)= ↑LVEF ↑6-min WT, ↑ NYHA
↑ QOL

WHITE et al, JACC 2006
28 HF pz
Eziologia ischemica e non ischemica
FU 3 mesi
Risposta (57%pz)= ↑LVEF ↑6-min WT,
↑ NYHA↑ QOL

Leyva *et al. Journal of Cardiovascular Magnetic Resonance* 2011, **13**:29
http://www.jcmr-online.com/content/13/1/29

Journal of Cardiovascular Magnetic Resonance

RESEARCH Open Access

Cardiac resynchronization therapy guided by late gadolinium-enhancement cardiovascular magnetic resonance

Francisco Leyva[1*], Paul WX Foley[2], Shajil Chalil[1], Karim Ratib[2], Russell EA Smith[1], Frits Prinzen[3] and Angelo Auricchio[4]

◆559 HF pz
-CAD 65.7%, DCM 34.3%
-CRT-D 16%, CRT-P 84%

◆CRT
-Posizionamento dell'elettrodo fuori da cicatrice (+CMR –S) 166
-Posizionamento dell'elettrodo in zona cicatriziale (+CMR +S) 43
-CMR non eseguita 350
Follow up fino 9.1 anni (media 1.8 anni)

RM NELLA RESINCRONIZZAZIONE CARDIACA

Leyva et al. Journal of Cardiovascular Magnetic Resonance 2011, 13:29
http://www.jcmr-online.com/content/13/1/29
Journal of Cardiovascular Magnetic Resonance

RESEARCH Open Access

Cardiac resynchronization therapy guided by late gadolinium-enhancement cardiovascular magnetic resonance

Francisco Leyva[1*], Paul WX Foley[2], Shajil Chalil[1], Karim Ratib[2], Russell EA Smith[1], Frits Prinzen[3] and Angelo Auricchio[4]

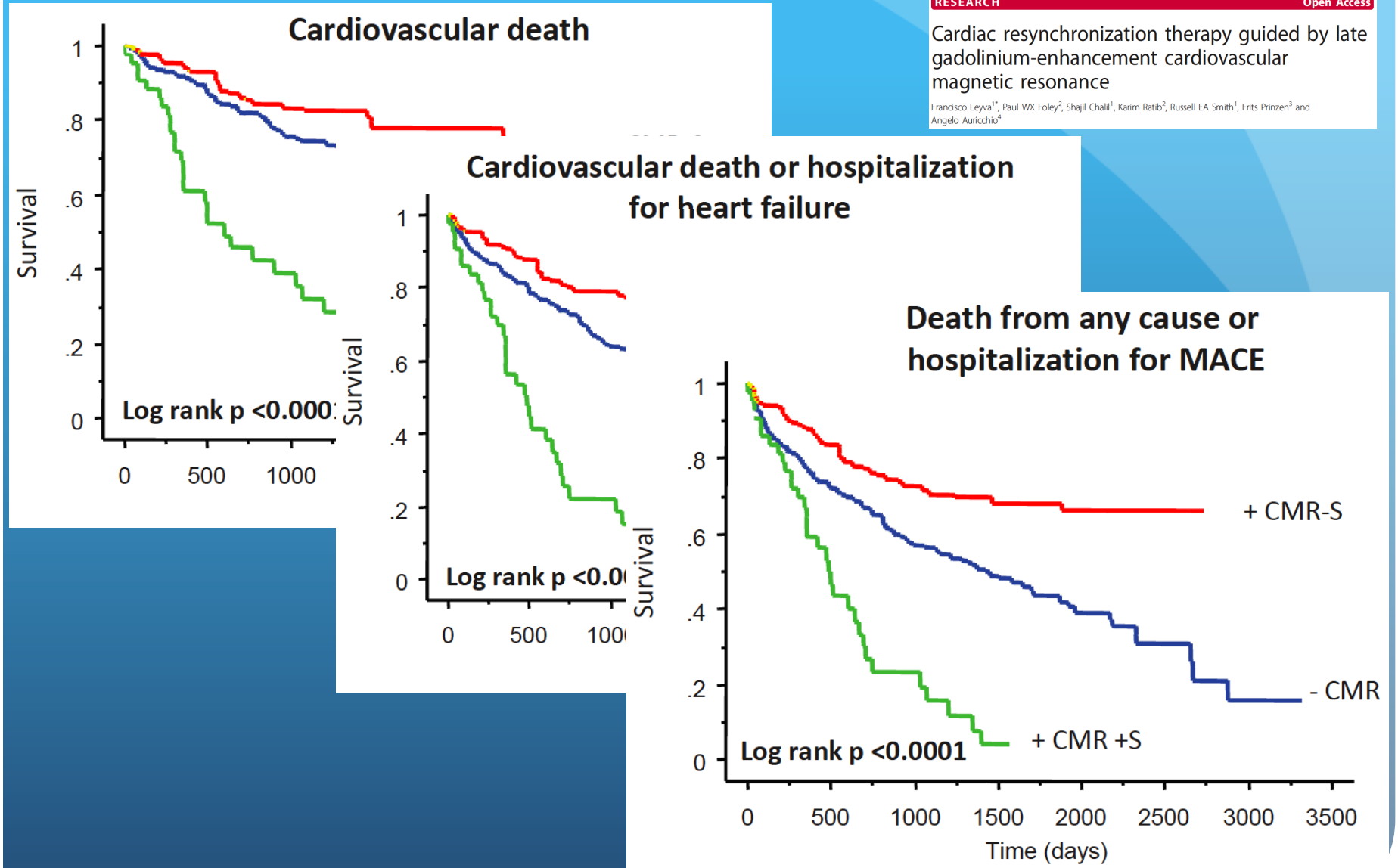

RM NELLA RESINCRONIZZAZIONE CARDIACA

Leyva et al. Journal of Cardiovascular Magnetic Resonance 2011, 13:29
http://www.jcmr-online.com/content/13/1/29

Journal of Cardiovascular Magnetic Resonance

RESEARCH Open Access

Cardiac resynchronization therapy guided by late gadolinium-enhancement cardiovascular magnetic resonance

Francisco Leyva[1*], Paul WX Foley[2], Shajil Challi[1], Karim Ratib[2], Russell EA Smith[1], Frits Prinzen[3] and Angelo Auricchio[4]

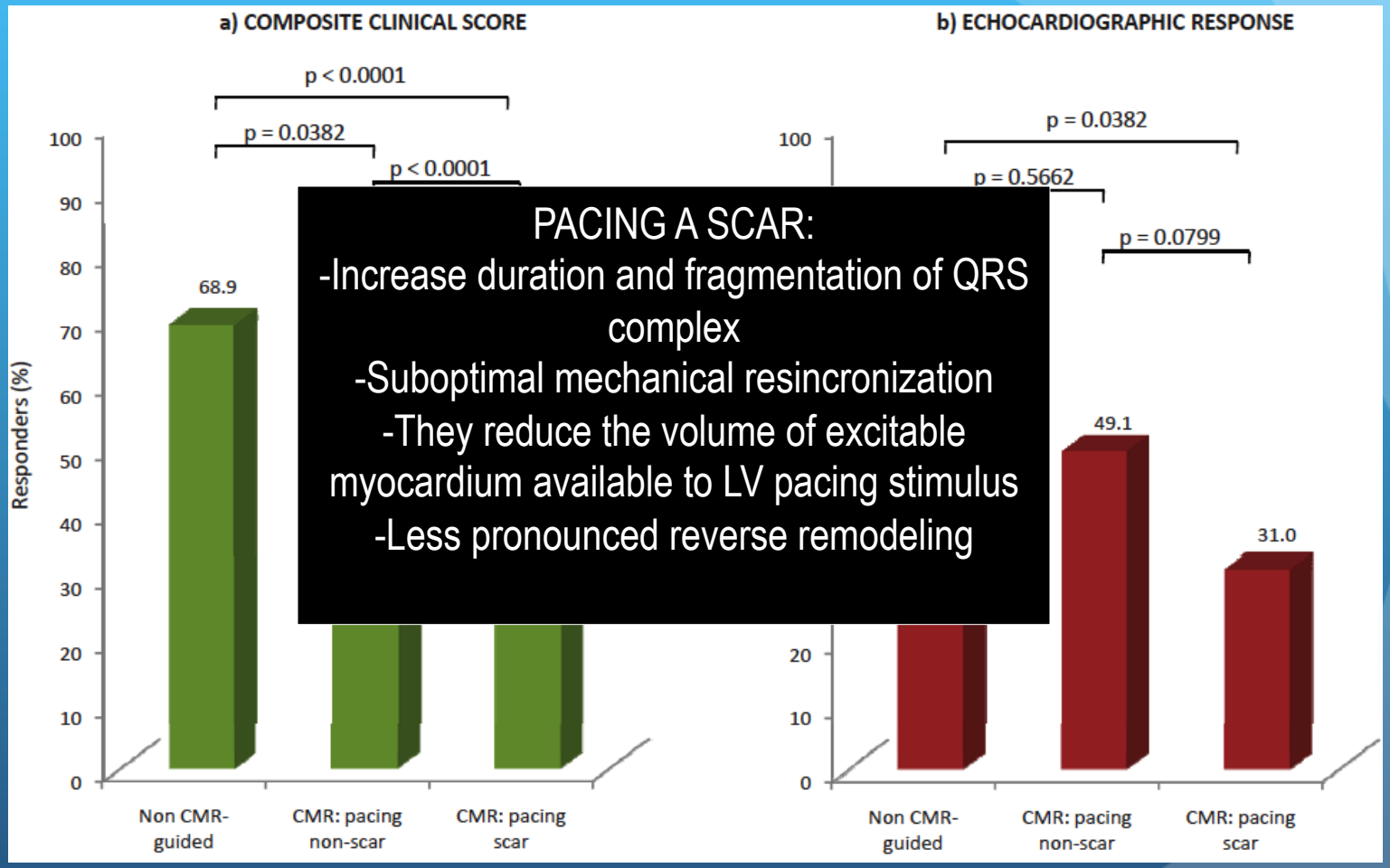

PACING A SCAR:
-Increase duration and fragmentation of QRS complex
-Suboptimal mechanical resincronization
-They reduce the volume of excitable myocardium available to LV pacing stimulus
-Less pronounced reverse remodeling

Scar tissue–guided left ventricular lead placement for cardiac resynchronization therapy in patients with ischemic cardiomyopathy: An acute pressure-volume loop study

Gerben Jan de Roest, MD,[a] LiNa Wu, MD,[a] Carel C. de Cock, MD, PhD,[a] Matthijs L. Hendriks, MPA,[a] Peter Paul H.M. Delnoy, MD, PhD,[b] Albert C. van Rossum, MD, PhD,[a,c] and Cornelis P. Allaart, MD, PhD[a]
Amsterdam, Zwolle, and Utrecht, The Netherlands

Am Heart J 2014;167:537-45

Viable Tissue Pacing

ΔSW +62% ± 51%, $P < .001$

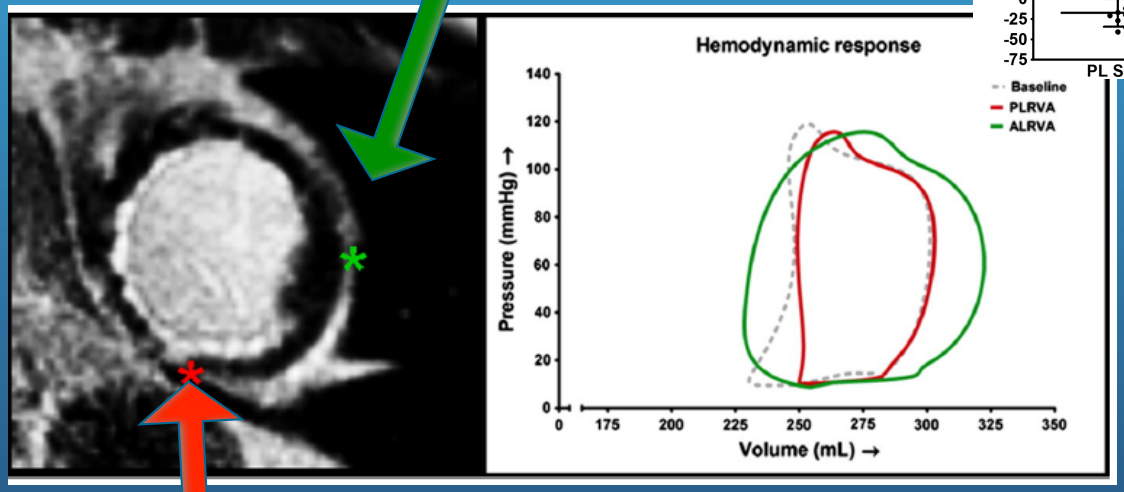

Scar Pacing

ΔSW −17% ± 17%, $P = .018$

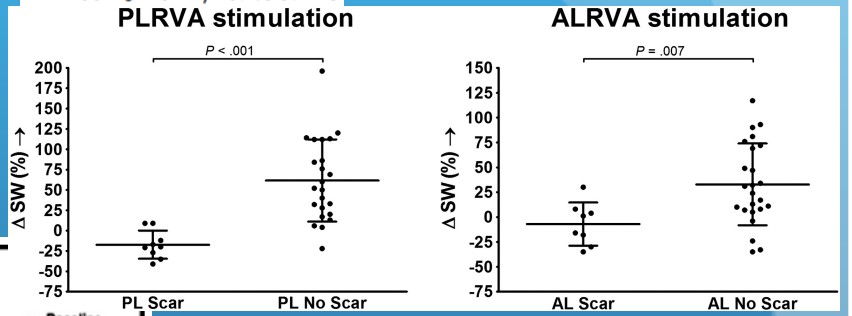

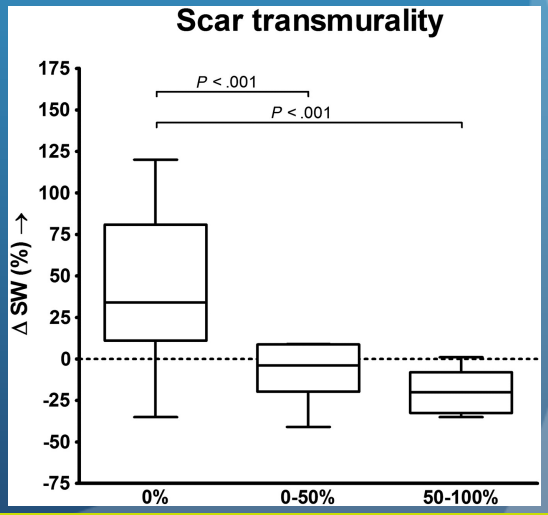

VALUTAZIONE DEL SISTEMA VENOSO CORONARICO

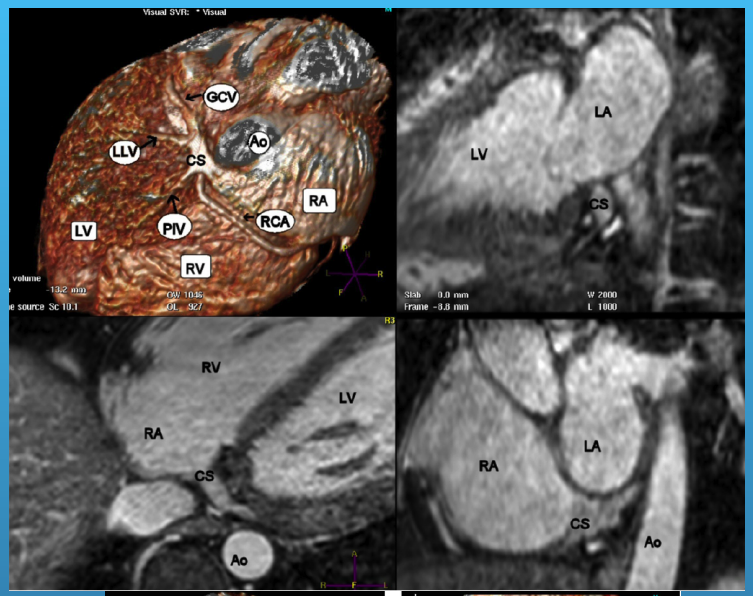

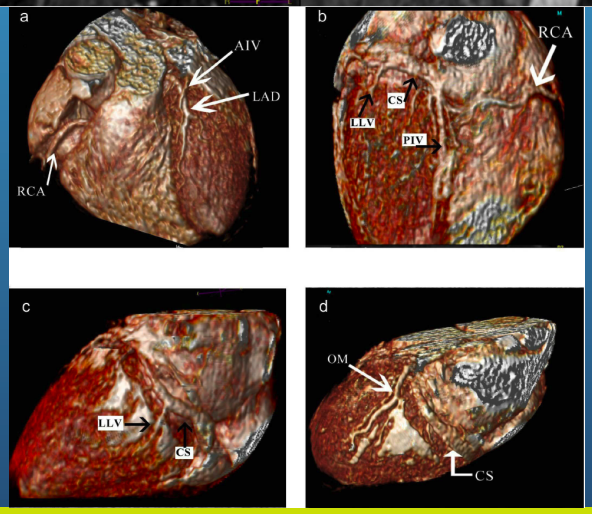

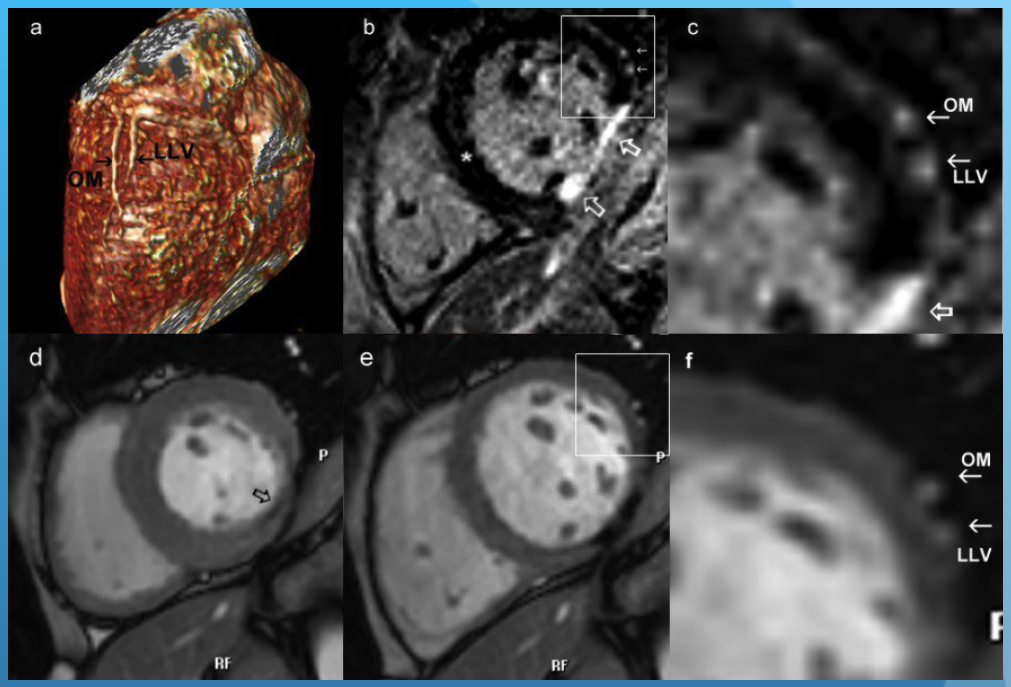

Journal of Cardiovascular Magnetic Resonance

BioMed Central

Research

Open Access

Visualization of coronary venous anatomy by cardiovascular magnetic resonance

John F Younger[1], Sven Plein[2,3], Andrew Crean[4], Stephen G Ball[2,3] and John P Greenwood*[2,3]

Journal of Cardiovascular Magnetic Resonance 2009, **11**:26

RM NELLA RESINCRONIZZAZIONE CARDIACA

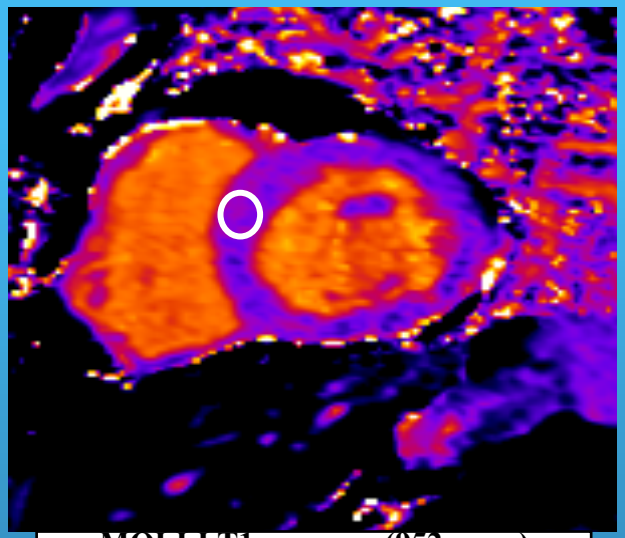

MOLLI T1 map pre (952 msec)
Valore normale ad 1.5 T = 950-960 msec

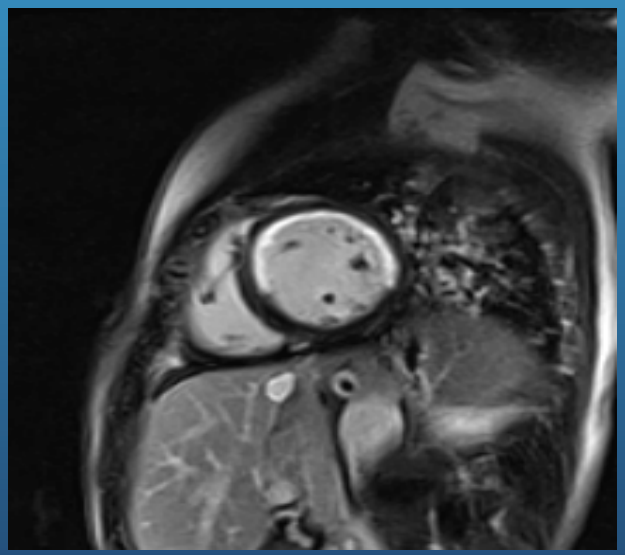

Assessment of Myocardial Fibrosis With Cardiovascular Magnetic Resonance
Nathan Mewton et al. JACC 2011

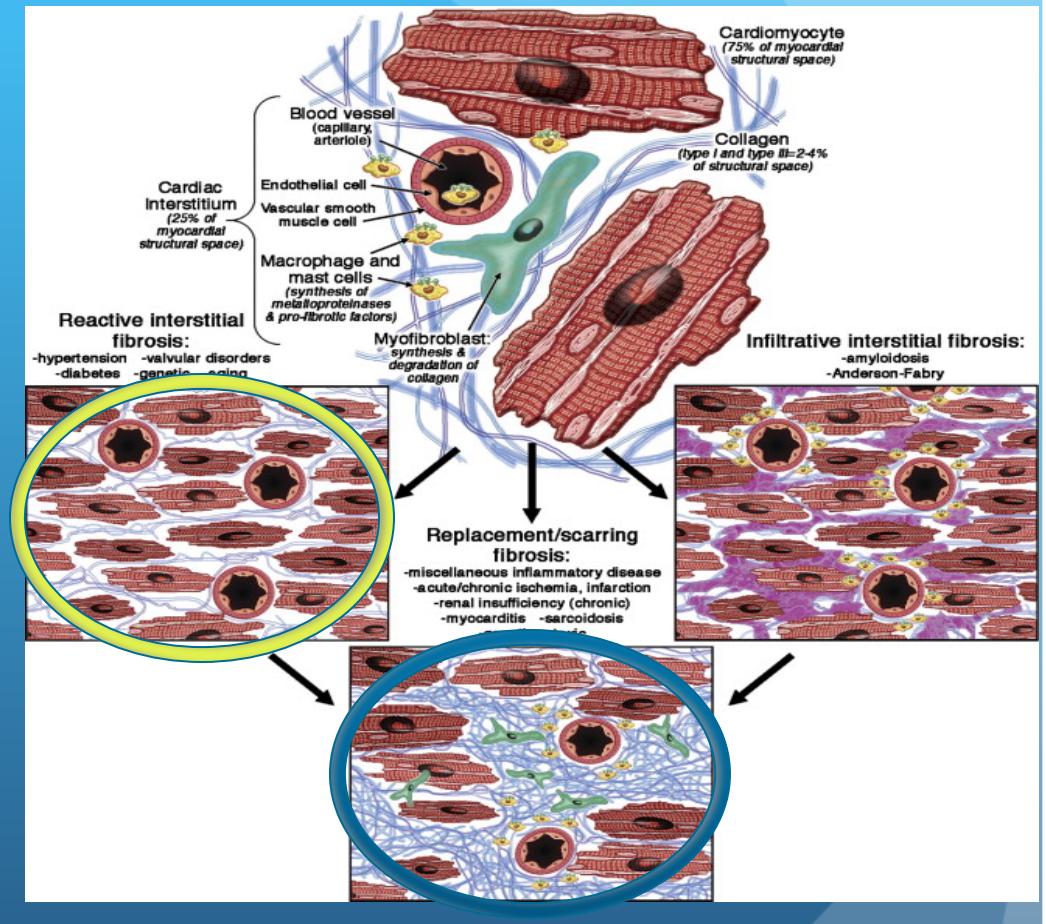

Yann Arthus-Bertrand

“La tecnologia non tiene lontano l’uomo dai grandi problemi della natura , ma lo costringe a studiarli piu’ approfonditamente”
Antoine de Saint-Exupery

GRAZIE